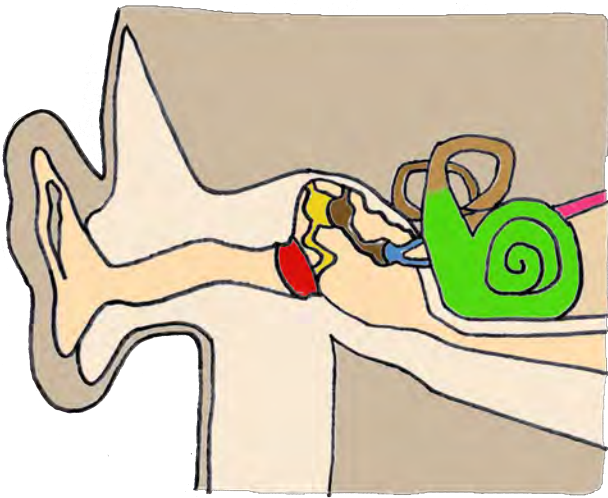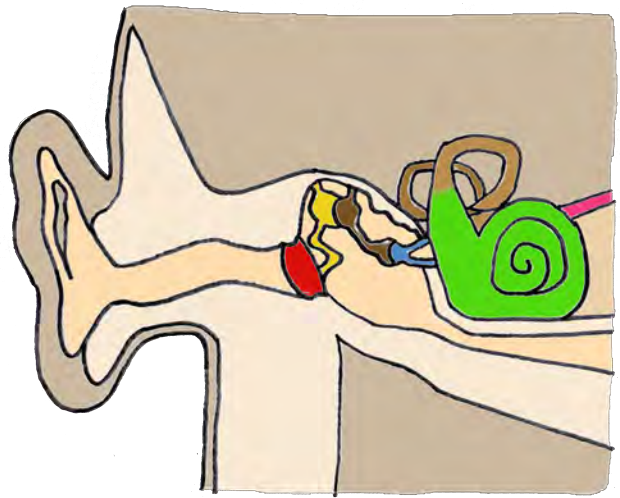
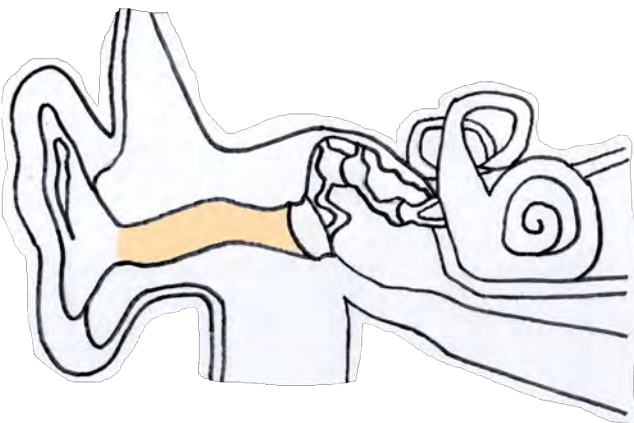


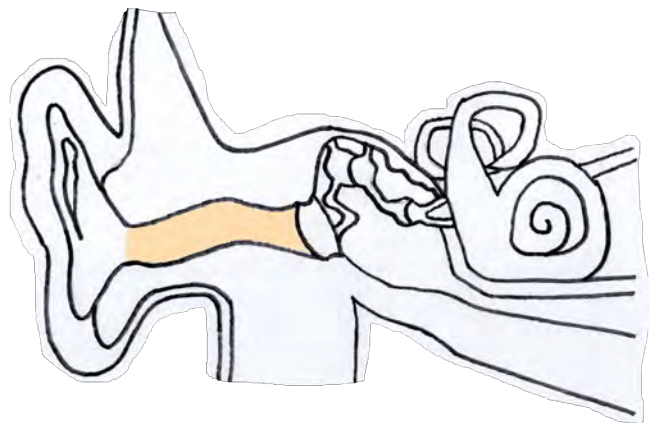
The human ear



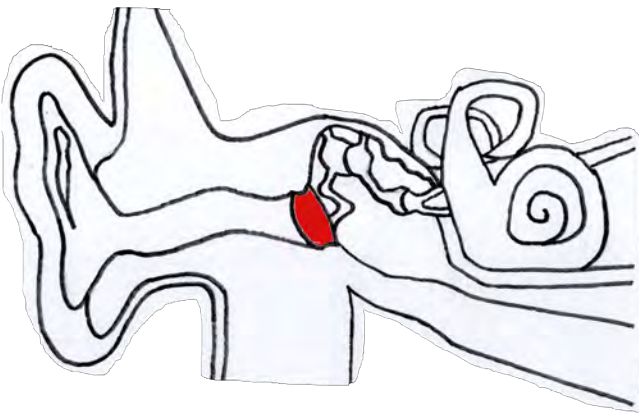
The human ear



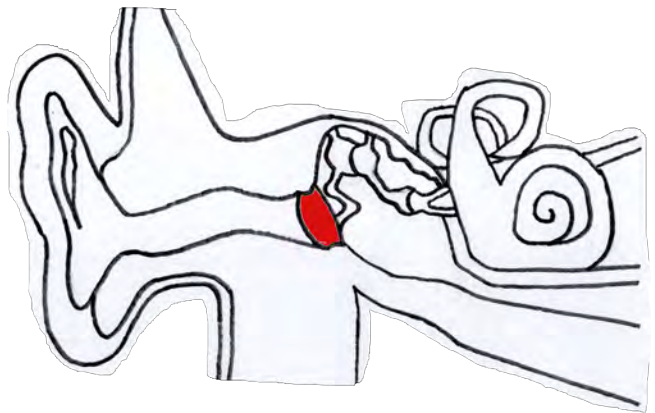
ear canal



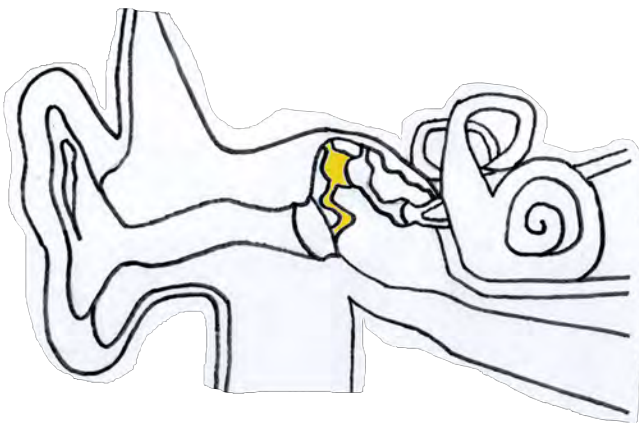
ear canal



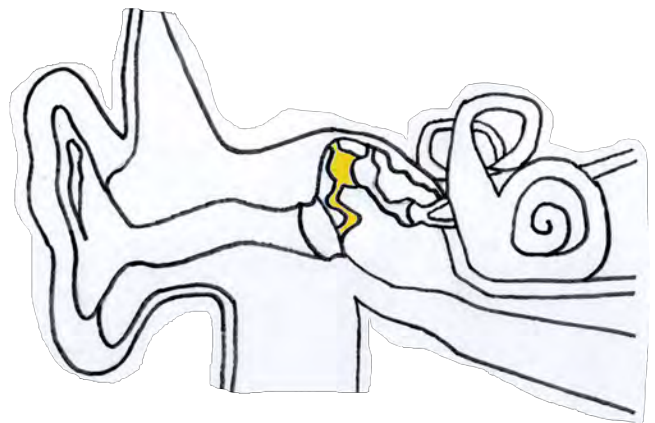
eardrum



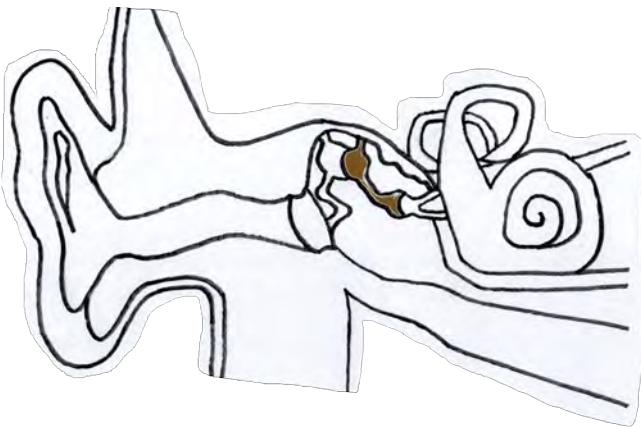
eardrum



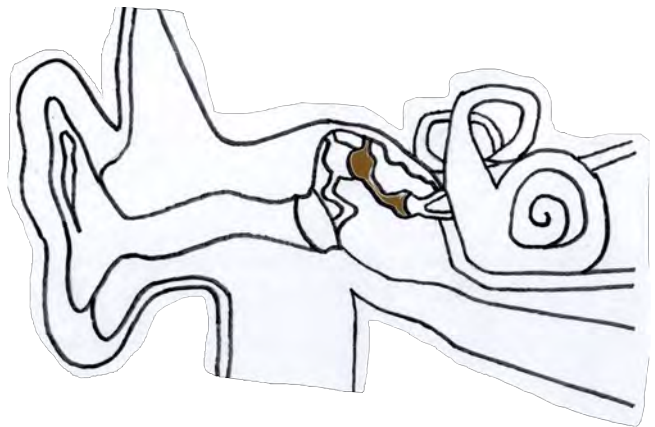
hammer



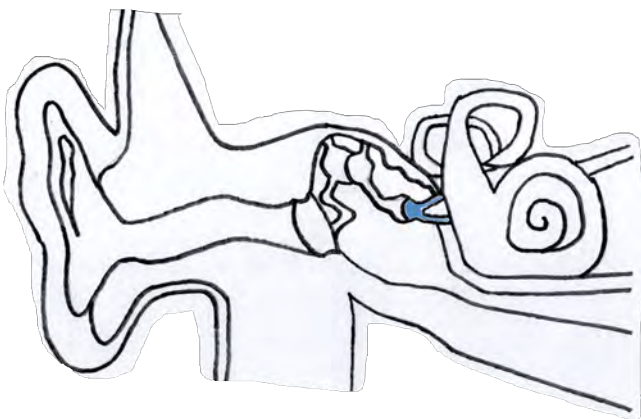
hammer



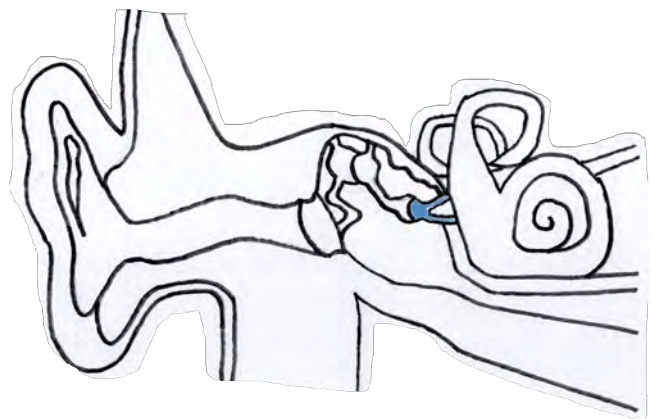
anvil



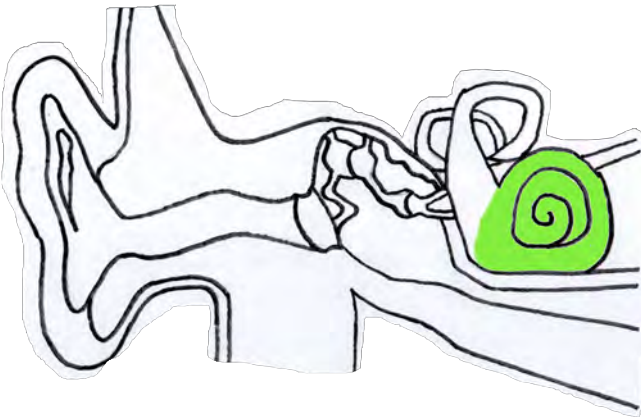
anvil



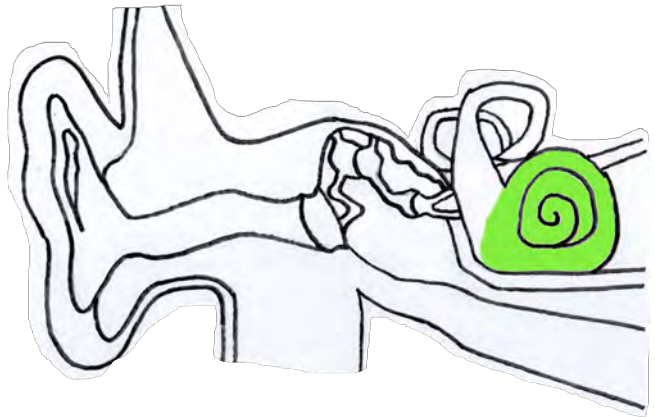
stirrup



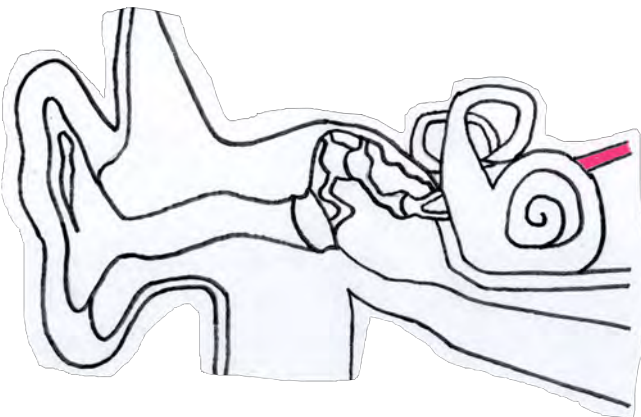
stirrup



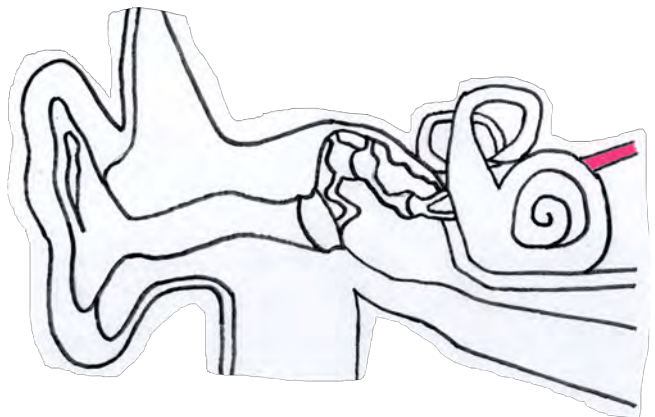
cochlea



cochlea



nerve



nerve